

Orbital ultrasonography for diagnosis and evaluation of retrobulbar vascular disorders

D. Imbrasienė^{1,2}, A. Paunksnis¹, J. Jankauskienė¹, D. Žaliūnienė¹, D. Stanislovaitienė¹, R. Karaliūtė¹

¹*Kaunas Medical University Eye Clinic,*

²*Lithuanian Academy of Physical Education*

Abstract

Diagnostic and differential diagnostic of orbital diseases are considered to be one of the most difficult problems in ophthalmology because most orbital pathologies display the same signs and symptoms. Condition of orbital tissues can be evaluated using three different radiology imaging techniques: A/B-scan ultrasonography, computed tomography, and magnetic resonance imaging. A/B-scan ultrasonography is highly informative, non-invasive and poses no risk on the patient, therefore may be repeatedly performed in order to evaluate treatment effectiveness or disease progression. Ultrasonography has become an extremely useful tool in assessment of orbital vascular disorders. Orbital vascular disorders are divided into two main groups: neoplasms and malformations. Vascular malformations are: cavernous sinus fistula, carotid-cavernous sinus fistula, dural-cavernous sinus fistula, superior ophthalmic vein thrombosis, orbital varix, arteriovenous malformation and orbital aneurysm. In this article, we present the case of a difficult superior ophthalmic vein thrombosis in which orbital ultrasonography imaging was used in confirming the diagnosis and evaluating treatment effectiveness.

Keywords: orbital A/B- scan ultrasonography, retrobulbar vascular disorders, superior ophthalmic vein thrombosis.

Introduction

Ultrasonography of the eye and orbit has been first used in the clinical practice a few decades ago and since then became a valuable method of diagnosing most of the eye and orbit diseases. The tissues lying in the orbit are quite miscellaneous comprising of soft tissues, fat, connective tissue diaphragms, nerves and blood vessels. Therefore it is often difficult to evaluate not only the affected tissues but the healthy ones as well [1]. One of the most complicated problems in ophthalmology appears to be diagnostics of the orbit diseases as they all tend to mimic one another, manifesting with very similar if not identical symptoms [2]. The symptoms of orbit diseases depend on the anatomic and physiologic eye position and the synchronic performance of the ocular motor nerves. Traumas, inflammations, orbit tumours do not only impair the optical system, but are frequently dangerous for the patient's life. Therefore early determination of the location, size, type and etiology of the lesion is essentially important to each doctor in choosing the treatment tactics right [3]. The correct diagnostics of variety of orbit diseases is only possible when cooperation of different specialities doctors exist [4,5,6].

Ultrasonography is highly informative, non-invasive and poses no risk on the patient, therefore may be repeatedly performed in order to evaluate treatment effectiveness or disease progression [7, 8]. This method may not require narcosis for children as it is painless and does not take long. Ultrasonography of the orbit is usually performed by doctor ophthalmologist, who is better aware of the physiology and pathology of the orbit than is radiologist. Whereas computed tomography as well as magnetic resonance imaging are subjected to radiologist [9]. Besides, the latter take quite some time, the patient is being radiated; little children may only be investigated

under narcosis. The full view of the orbit cannot be attained using these methods as the equipment is set to operate under some certain mode therefore in some cases pathologic alterations may not be detected. Up to date ultrasound examination remains the gold standard for histological evaluation of orbit alterations in vivo [9]. The main drawback of ultrasound orbit scanning technique is difficulty to assess alterations in the apex of the orbit, as high frequency ultrasound vibration, used in ophthalmological practice do not penetrate well into the back part of the orbit. If the pathological process in the apex of the orbit is being suspected, computed tomography or MRI scanning could be the more informative tools [9-14].

Vascular lesions are among the most common orbital abnormalities encountered in ultrasonography [15]. Vascular lesions of orbit are divided into two main group: neoplasms and malformations. Vascular malformations are: cavernous sinus fistula, carotid-cavernous sinus fistula (fast flow), dural-cavernous sinus fistula (slow flow), superior ophthalmic vein thrombosis, orbital varix, arteriovenous malformation, orbital aneurysm [9].

Carotid - cavernous sinus fistula (fast flow) usually develops as a result of head traumas [16]. Spontaneous or congenital carotid cavernous sinus fistulas are quite uncommon [17, 18]. Carotid - cavernous sinus fistula has some characteristic clinical features. Ultrasound diagnostics of these lesions is not difficult [19]. Clinical signs of carotid - cavernous sinus fistula are dilated episcleral vessels, pulsating exophthalmus, conjunctive suffusion, audible murmur, in some cases – raised eye-pressure [8]. Ultrasonography is highly informative method in diagnostic of this pathology [20]. The dilated superior ophthalmic vein, which is most often invisible in the normal eye manifests as a classical sign of this disorder [16]. It is best seen between superior rectal muscle, optic

nerve and superior internal part of the eye and superior orbital gap [2]. Other signs of carotid-cavernous sinus fistula are orbit soft tissue swelling (widening of the retrobulbar space), widening of external eye muscles, compression of optical nerve because of accumulation of subarachnoid fluid [9, 17, 19]. Uveal detachment may be also detected. Venous dilation degree depends on the speed of blood flow in the fistula. Reflectability of dilated vein in scanogram A is very low and the blood stream is very vigorous [8]. Venous pulsation may sometime be visualised in both scanogram A and B. Dopler examination may be very informative in these cases [9, 13]. The alterations are usually solid in consistence (compression test) because of the vigorous blood stream inside the lesion. Other confluent vein dilation may be also detected (internal collateral or vertical veins, as described by Ossoinig et al.)

Dural cavernous sinus fistula (slow blood flow) is also known as "red eye bypass syndrome". It usually develops suddenly in middle-aged or elderly women. Episcleral vessel dilation, slight exophthalmus, heightened eye-pressure is typical to this disorder [21]. No murmur or eye pulsation is present in this case [16]. Retrobulbar space is slightly widened in the echogram due to the swelling of the soft tissues in the affected orbit [22, 23]. Superior ophthalmic vein is usually unaltered or slightly dilated. Reflectability of the dilated vein is low or medium, but higher than in cases of carotid artery and cavernous sinus fistula. Inner reflectability of the vein heightens supposedly due to partial thrombosis of slow blood stream fistula. Ultrasound doplerography is usually of little use. If the vein is not dilated and rectal muscles are widened, ultrasound examination results resemble those of endocrine ophthalmopathy [24].

Superior ophthalmic vein thrombosis may develop in cases of carotid - cavernous or dural- cavernous sinus fistulas. Exophthalmus, swelling of conjunctives or lids, in some cases dilation of the superior ophthalmic vein are typical for thrombosis of the superior ophthalmic vein [25]. The blood stream is very slow or absent in these cases. The reflectability of such vein is medium due to the clotted blood.

Primary orbit haemorrhoids are a congenital disorder. They are usually unilateral and in just some cases, they may be bilateral [26]. Unstable exophthalmus is typical to orbit haemorrhoids, depending on the head position of Valsalve testing [9, 27]. Raised venous blood pressure during Valsalve manoeuvre conditions passive blood accumulation in the altered venous interspaces. Hollowing of the eye may occur because of fat tissue necrosis in the affected orbit. In cases of contraction of the haemorrhoids, alterations may be absent in the routine examination. But Valsalve manoeuvre or leaning forward makes venous interspaces bulge and look like delimited alterations of low or medium reflectability in the orbit [2]. Haemorrhoids may be pipe-shaped or resemble huge derivatives [16]. Haemorrhoids are usually being compressed, but inner blood flow is unremarked due to the access of venous blood. It should be taken into the account that the slight superior ophthalmic vein dilation may be observed in both orbits when the patient leans forward. Ultrasound

doplerography and orbit venography are essential for the diagnostics of orbit haemorrhoids [26].

Arterial-venous alterations may be congenital or they may develop after head traumas. These lesions are usually diffuse, irregular in shape, as they develop from matted, altered arteries and veins. Their inner structure is irregular due to the rapid blood flow of very low reflectability and vessel walls of very high reflectability. A scanogram may reveal rapid blood stream especially in ultrasound doplerography. The net of blood vessels in these lesions is very cloggy. The altered tissues are usually soft and may be easily compressed. In cases of arterial-venous disorders soft orbit tissue swelling may occur, resulting in secondary glaucoma or in rare cases serous uveal detachment [22, 23].

Arterial aneurisms in the orbit are clearly delimited, their inner reflectability is low and their inner structure is regular [16]. They are richly vascularised, therefore easily detectable in scanogram A and ultrasonographic doplerography [2]. The altered tissues are easily compressible. Orbit aneurisms are usually located and often take the front part of the orbit. Carotid artery and cavernous sinus fistulas are usually more spread and take larger territory – they usually spread from superior internal quadrant to the apex of the orbit [2, 8].

Method

We present a case of a right superior ophthalmic vein thrombosis. In this case orbital ultrasonography imaging was used in confirming the diagnosis and evaluating treatment effectiveness. The ultrasonography of the orbit and measurements of rectus extraocular muscles (medial, lateral, inferior and superior rectus) were performed by A/B mode Mentor™ Advent ultrasonic diagnostic imaging system with a 7.5 MHz transducer. The axial and longitudinal scans were used for the examination of orbital tissues. The probe was placed on the side of the globe opposite the muscle to be examined. Ultrasonography of the right orbit showed marked distortion of the periorbital soft tissue. Right retrobulbar space was wider than the left. The right superior and medial recti muscles were noted to be enlarged and the right superior ophthalmic vein was dilated when compared with the normal left side.

Case report

A 68-year-old woman presented to ophthalmologist with a one month history of painless eyes swelling and right eye redness. There was no history of head injury. She was taking antihypertensive drugs and was suffering from allergies to many of medicines. Her general practitioner had initially suspected a diagnosis of allergic conjunctivitis and started with steroid eye drops and antiallergic oral medication, but this had not alleviated symptoms. After one month treatment on ocular examination there was found a conjunctival chemosis in both eyes and a massive broad subconjunctival hemorrhage in the right eye. Best-corrected visual acuity was normal. Extraocular movements were full. Pupillary reactions and fundoscopy appeared normal. Three months later patient presented with painfull right eye swelling. There was a mild

decreased visual acuity in the right eye (OD-0.8; OS-1.0) and moderate ophthalmoplegia (decreased ocular motility) of upward gaze. Right proptosis was of 3mm compared with the left eye. The proptosis was non-pulsatile and no bruit was audible over the globe. There was a significant difference in the intraocular pressure: 27.4 mmHg in the right eye and 20.9mmHg in the left eye. On ocular examination there was found a right-sided pericorneal injection, tortuous dilated conjunctival vessels, conjunctival chemosis from the lower-lateral side of an eye-ball and a moderate neovascularization in the iris. Fundoscopy of the right eye revealed obscured margins of the optic nerve head disc, mild retinal edema around the disc and dilated hyperemic retinal veins. Ultrasonography of the right orbit showed marked distortion of the periorbital soft tissue. Right retrobulbar space was wider than the left. The right superior and medial recti muscles were noted to be enlarged and the right superior ophthalmic vein was dilated when compared with the normal left side (Table1).

Table 1. Extraocular muscles thickness measured using ultrasound B-scan

Eye muscle \ Eye	Medial, mm	Inferior, mm	Lateral, mm	Superior, mm
OD	6.11-7.47	6.16	5.63	5.81
OS	4.75	4.69	4.68	4.85

The MR images confirmed US findings, the cavernous sinus appeared within normal limits. The clinical diagnosis was that of a right superior ophthalmic vein thrombosis. The patient was treated symptomatically. Her condition improved with reduction of the proptosis (OD-20mm, OS-19,5mm) over two months. Repeated US imaging of the orbit demonstrated normalisation of the right eye extraocular muscles thickness; the superior ophthalmic vein dilation and orbit soft tissue swelling in supero-internal part of the orbit space, however, were seen (Table 2).

Table 2. Extraocular muscles thickness measured using ultrasound B-scan after 2 months of treatment

Eye muscle \ Eye	Medial, mm	Inferior, mm	Lateral, mm	Superior, mm
OD	4.42	4.33	4.54	4.7
OS	4.75	4.69	4.68	4.85

Orbital sonography was repeated 1 month later. The report was: significant improvement with regression of the right orbital soft tissue swelling; superior ophthalmic vein was visible but it's diameter was narrowed (Fig. 1-6). The visual acuity improved, the intraocular pressure elevation, however, remained. It was diagnosed secondary glaucoma.

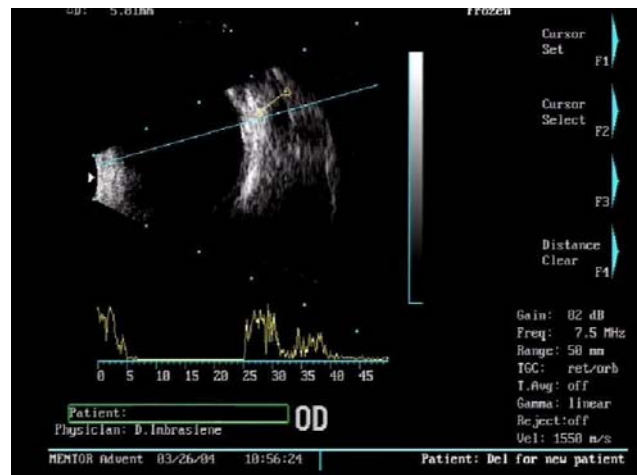


Fig. 1. Using transversal vertical B-scan method for the upper medial part of the left orbit, cross-section of enlarged superior ophthalmic vein is seen, superior muscle is thickened (it's width 5.81). Low-reflectability signals are seen in the projection of cross-section of superior ophthalmic vein in the A-scan

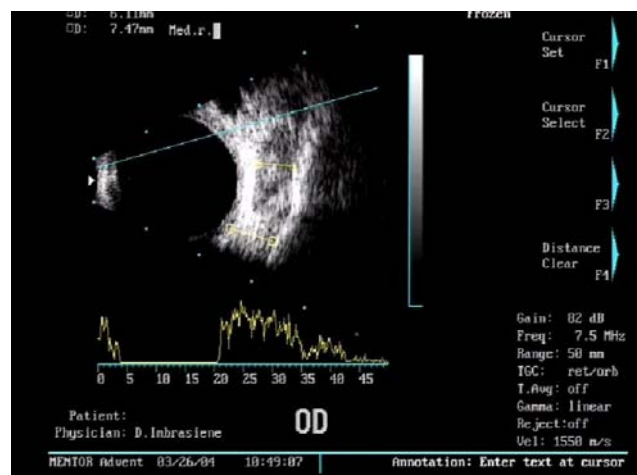


Fig. 2. Using transversal vertical B-scan method for the right orbit, cross-section of superior ophthalmic vein and thickened medial muscle (its width 6.11-7.47 mm) are seen

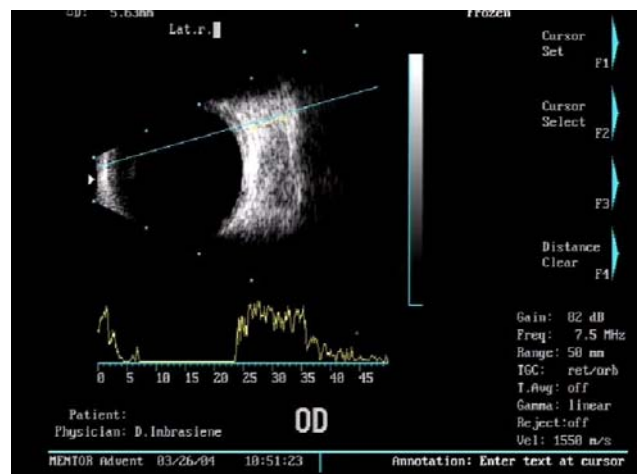


Fig. 3. In ultrasonographic B-scan of the lateral part of the orbit, thickened lateral muscle is seen (its width 5.63 mm)

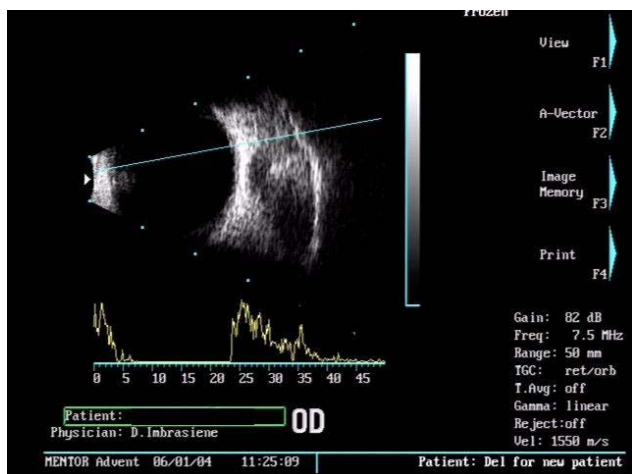


Fig. 4. Repeated examination after 2 months of treatment. Using transversal vertical B-scan method for the right orbit, superior ophthalmic vein with medial collateral vein is still seen

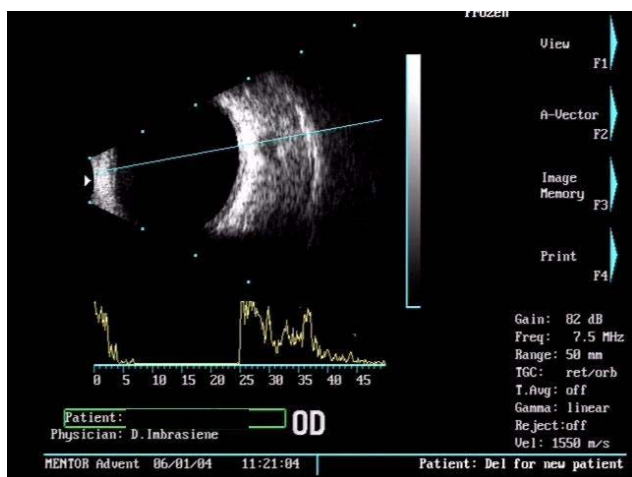


Fig. 5. Using longitudinal B-scan method after 2 months of treatment, cross-section of enlarged superior ophthalmic vein is still seen

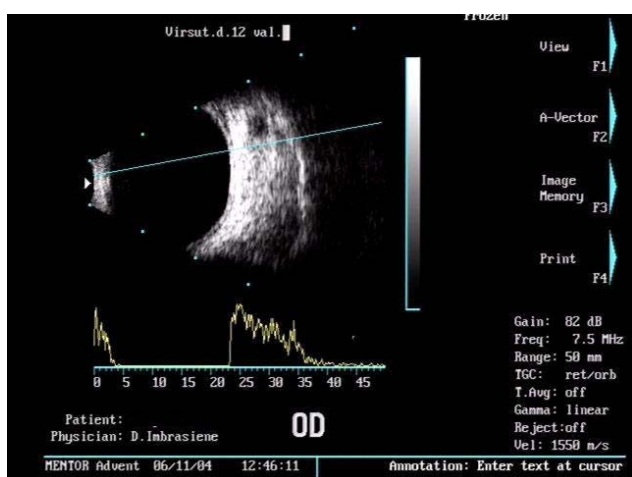


Fig. 6. Using longitudinal B-scan method after 2.5 months of treatment, cross-section of enlarged superior ophthalmic vein is still seen.

Conclusion

Ultrasonography was very highly informative and non-invasive diagnostic method in our case, because dilated superior ophthalmic vein, widening of the retrobulbar space and widening of external eye muscles is gold standard of vascular malformations of orbit. Ultrasonography has several practical advantages compared with CT and MRI, because it is cheap and isn't dangerous diagnostic method, so we repeatedly performed it in order to evaluate treatment effectiveness.

References

1. Kahn M. T. Color Doppler orbital hemodynamics in healthy individuals and patients with vascular disorders in Taiwan. *Orbit*. 2008. Vol. 27(1). P.25-30.
2. Imbrasienė D. Akiduobės ir regos nervo ultragarsinė diagnostika: I d. Kaunas: Vitae litera. 2007.
3. Héran F. Imaging of orbital masses. *Neurochirurgie*. Apr-Jun 2010. Vol. 56(2-3). P.89-120.
4. Müller - Forell W., Pitz S. Orbital pathology. *Eur J Radiol*. 2004. No. 49. P.105 – 142.
5. Bergès O, Koskas P, Lafitte F, Piekarski J. D. Sonography of the eye and orbit with a multipurpose ultrasound unit. *J Radiol*. 2006. Apr.87(4 Pt 1). P.345-353. Review.
6. Wei R, Cai J, Ma X, Zhu H, Li Y. Imaging diagnosis of enlarged superior ophthalmic vein. *Zhonghua Yan Ke Za Zhi*. 2002. Jul. Vol.38(7). P.402-404.
7. Buschman W., Haigis W. Differential echographic diagnosis in small tissue – exemplified by the orbits. *Ultraschall Med*. 1982. Vol.3(4). P.204 – 208.
8. Byrne S. R., Glaser J. S. Orbital tissue differentiation with standardized echography. *Ophthalmol* 1983. Vol. 90(9). P. 1071–1090.
9. Beatty S., Good P. A., McLaughlin J., O'Neill E. C. Echographic measurements of the retrobulbar optic nerve in normal and glaucomatous eyes. *Br J Ophthalmol*. 1998. Vol.82. P. 43 – 47.
10. Byrne S. F., Green R. L. *Ultrasound of the Eye and Orbit*. St.Louis: Mosby Yearbook. 1992.
11. Delcker A., Martin T., Tegeler C. Magnetic sensor data acquisition for three – dimensional ultrasound of the orbit. *Eye*. 1998. Vol.12 (Pt.4). P. 725 – 728.
12. Niehaus L., Neuhauser H., Meyer B. U. Transient visual blurring, retro-orbital pain and repetitive involuntary movements in unilateral carotid artery occlusion. *Clin Neurol Neuroch*. 1998. Vol.100(1). P.31-32.
13. Stefanczyk L., Kaurzel Z., Kazanek M., Jedrzejczyk S. Carotid – cavernous fistula – diagnostic possibilities of color doppler ultrasonography. *Klin Ocsna*. 1996. Vol. 98. P. 51-53.
14. Kirsch E, Hammer B, von Arx G. Graves' orbitopathy: current imaging procedures. *Swiss Med Wkly*. 2009 Oct 31. Vol.139(43-44). P.618-623. Review.
15. Héran F. Imaging of orbital masses. *Neurochirurgie*. 2010 Apr-Jun. Vol.56(2-3). P.89-120.
16. Agarwal A. *Handbook of Ophthalmology*. SLACK Incorp. 2006.
17. Atta H. R., Dick A. D., Hamed L. M., Byrne S. F., gendron E. K., Hughes R. L., Glaser J. S. Venous stasis orbitopathy: a clinical and echographic study. *Br. J. Ophthalmol*. 1996. Vol. 80. P.129-134.
18. Kolasa P., Kaurzel Z. Post-traumatic pulsating exophthalmus coexisting with congenital carotid-cavernous fistula. *Neurol Neurochir Pol*. 2001. Vol. 35(5). P.58-63.
19. Barakova D., Kuchynka P. Echography of carotid-cavernous fistulae. *Cesk Slov Oftalmol*. 1998. Vol. 54(5). P.319-22. Medline.
20. Feiner L., Bennett J., Volpe N. J. Cavernous Sinus Fistulas: Carotid Cavernous Fistulas and Dural Arteriovenous Malformations. *Curr Neurol Neurosc Ref*. 2003. Vol.3(5). P. 415-420.

21. **Kawaguchi S, Sakaki T, Uranishi R.** Color Doppler flow imaging of the superior ophthalmic vein in dural arteriovenous fistulas. *Stroke*. 2002 Aug. Vol.33(8). P.2009-2013.
22. **Lukasik S.** Orbital pathology. *Am. J. Ophthalmol.* 1993. Vol. 46. P.540-51.
23. **Nelson C. C., Cartwright M. J.** Orbital diagnosis and imaging. *Curr Opin Ophthalmol.* 1992. Vol. 3(5). P. 623 – 631.
24. **Given – Wilson R., Pope R. M., Michell M. J., Cannon R., McGregor A. M.** The use of real – time orbital ultrasound in Graves' ophthalmopathy: a comparison with computed tomography. *Br. J. Radiol.* 1989. Vol. 62. P. 705 – 709.
25. **Konuk O, Onaran Z, Ozhan Oktar S, Yucel C, Unal M.** Intraocular pressure and superior ophthalmic vein blood flow velocity in Graves' orbitopathy: relation with the clinical features. *Graefes Arch. Clin. Exp. Ophthalmol.* 2009 Nov. Vol.247(11). P.1555-1559. Epub 2009 Jul 16.
26. **Yazici B., Yazici Z., Geliksen O.** An unusual case: Bilateral orbital varices. *Acta Ophthalmol Scand.* 1999. Vol. 77. P. 453-455.
27. **Barakova D., Kuchynka P. Prochazkova S., Simunkova J.** Echographic findings in orbital varices. *Cesk Slov Oftalmol.* 1998. Vol. 54(5). P. 315-8. Medline.

D. Imbrasienė, A. Paunksnis, J. Jankauskienė, D. Žaliūnienė, D. Stanislovaitienė, R. Karaliūtė

Ultragarsinė kraujagyslinių akiduobės pokyčių diagnostika

Reziumė

Akiduobės ligų diagnostika ir diferencinė diagnostika yra vienas sudėtingiausių oftalmologijos klausimų, nes daugelio akiduobės ligų požymiai tokie patys arba labai panašūs. Akiduobės audinių būklė tiriama trimis pagrindiniais radiologinio tyrimo metodais: ultragarsinio A/B skenavimo, kompiuterinės tomografijos ir branduolinio magnetinio rezonanso. Ultragarsinis A/B skenavimo metodas yra gana informatyvus, neinvazinis ir nekenksmingas ligoniui, todėl jį galima dažnai kartoti ir taip įvertinti gydymo veiksmingumą arba ligos progresavimą. Ultragarsiniai tyrimai labai svarbūs akiduobės kraujagyslinių pokyčių diagnostikai. Kraujagysliniai akiduobės pokyčiai skirstomi į dvi dideles grupes - auglius ir kitus pokyčius. Kitų pokyčių grupei priklauso miego arterijos ir akytojo ančio fistulė, kietojo smegenų dangalo ir akytojo ančio fistulė, viršutinės akies venos trombozė, akiduobės veniniai mazgai, arteriniai-veniniai pokyčiai, akiduobės arterijų aneurizma. Straipsnyje aprašomas sudėtingas viršutinės akies venos trombozės atvejis, kai diagnostikai ir gydymo efektyvumui vertinti buvo naudojamas ultragarsinis skenavimas.

Pateikta spaudai 2010 09 30